



PRESENTING CLINICAL SIGNS

History: Previously diagnosed with cardiac disease. Coughing with movement. Mild pulmonary crackles. Receiving furosemide 2 mg BID and pimobendan 0.625 mg BID.

DATE

4/21/23

ECHOCARDIOGRAPHIC FINDINGS

2D, M-mode, and Doppler study.

PERFORMED BY:

Diane McFadden

INTERPRETED BY

Keith Blass, DVM,
MS, DACVIM
(Cardiology)

There is mild left atrial dilation. The mitral valve leaflets are mildly thickened and exhibit systolic prolapse. A mild to moderate jet of eccentric mitral regurgitation is present. There is mild left ventricular dilation. Left ventricular systolic function is normal. The aorta and aortic valve are normal. Right atrial and right ventricular dimensions are normal. The tricuspid valve leaflets are mildly thickened, and a mild jet of tricuspid regurgitation is present. TR velocity does not suggest the presence of pulmonary hypertension. The pulmonary artery and pulmonic valve are normal. No shunting lesions are visualized. No pericardial effusion or cardiac masses are seen.

PATIENT

Jolene Zanetti

LA - 20.4 mm
LVIDd - 20.4 mm
LVIDs - 11.2 mm
FS - 39.9%
RA - 13.5 mm
LVOT - 0.91 m/s
RVOT - 0.44 m/s
TR - 2.16 m/s

SPECIES

Canine

ASSESSMENT/RECOMMENDATIONS

Degenerative mitral and tricuspid valve disease

BREED

Chihuahua

This examination demonstrates regurgitation of blood across Jolene's mitral and tricuspid valves resulting from degenerative valve disease. Jolene's tricuspid valve disease is mild, and appears to be well-compensated at this time. Her mitral valve disease is a bit more advanced, as Jolene has mild to moderate mitral regurgitation present, with mild secondary dilation of both her left atrium and left ventricle, though her left ventricular systolic function is normal. As only mild left heart chamber dilation is present, it's unlikely that Jolene's cough is cardiogenic in origin, and it would be surprising if her pulmonary crackles were to be due to the presence of cardiogenic pulmonary edema.

SEX

FS

Thoracic radiographs are recommended to further evaluate Jolene's cough and pulmonary crackles.

AGE

13 y

Continued use of pimobendan is warranted based on this exam. As for furosemide, continued use would be warranted if the medication has improved any previous or current clinical signs. Additional therapy, such as a cough suppressant and/or anti-inflammatory medication, may potentially be warranted based on the results of the recommended radiographs.

WEIGHT

5.6 lb

A recheck echocardiogram is recommended in 9 months. Repeat thoracic radiographs are recommended if clinical signs compatible with congestive heart failure develop.

HOSPITAL NAME

Heart + Paw

REFERRING VET

Dr. Marmolejo



DATE

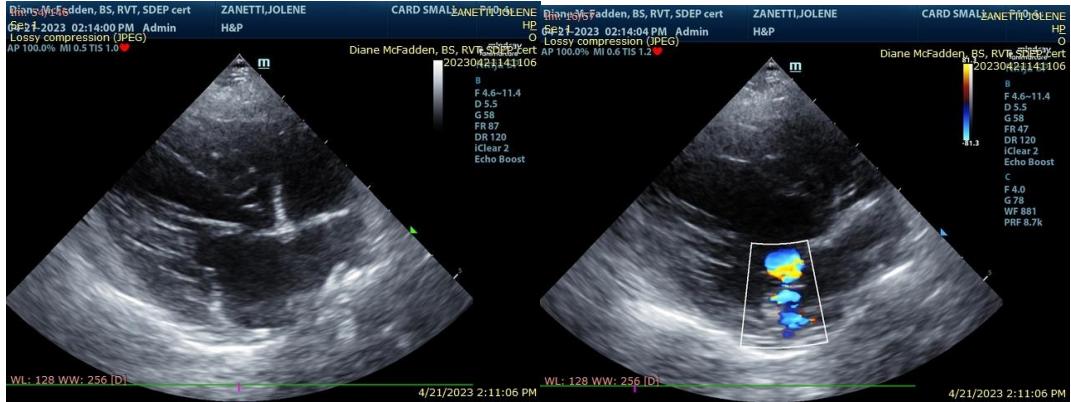
4/21/23

PERFORMED BY:

Diane McFadden

INTERPRETED BY

Keith Blass, DVM,
MS, DACVIM
(Cardiology)



PATIENT

Jolene Zanetti

SPECIES

Canine

Keith Blass, DVM, MS, DACVIM (Cardiology)
KeithBlass@gmail.com
631-804-5754

BREED

Chihuahua

SEX

FS

AGE

13 y

WEIGHT

5.6 lb

HOSPITAL NAME

Heart + Paw

REFERRING VET

Dr. Marmolejo

The information and recommendations provided are based on the images presented by the referring veterinarian. No evaluation can be communicated regarding pathology that was not visible in the image/video clips provided.

Thank you for this referral. If the clinical or image interpretation does not parallel your findings or if I can be of any further assistance please contact me.